

Retinal Periphlebitis

Category(ies): Retina, Vitreous

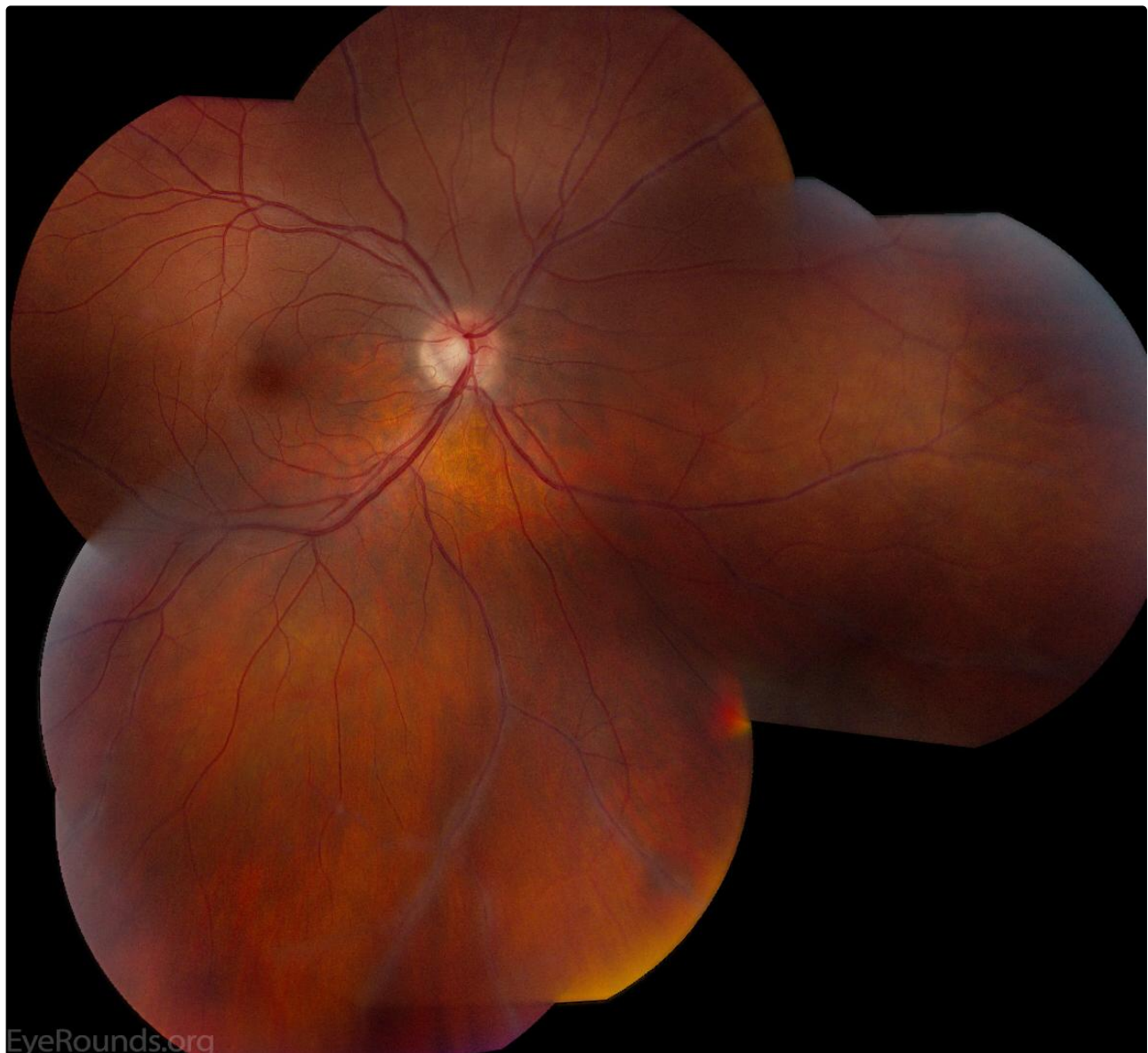Contributor: [Tressa Larson, OD, FAAO](#)

Photographer: Andrea Starkweather



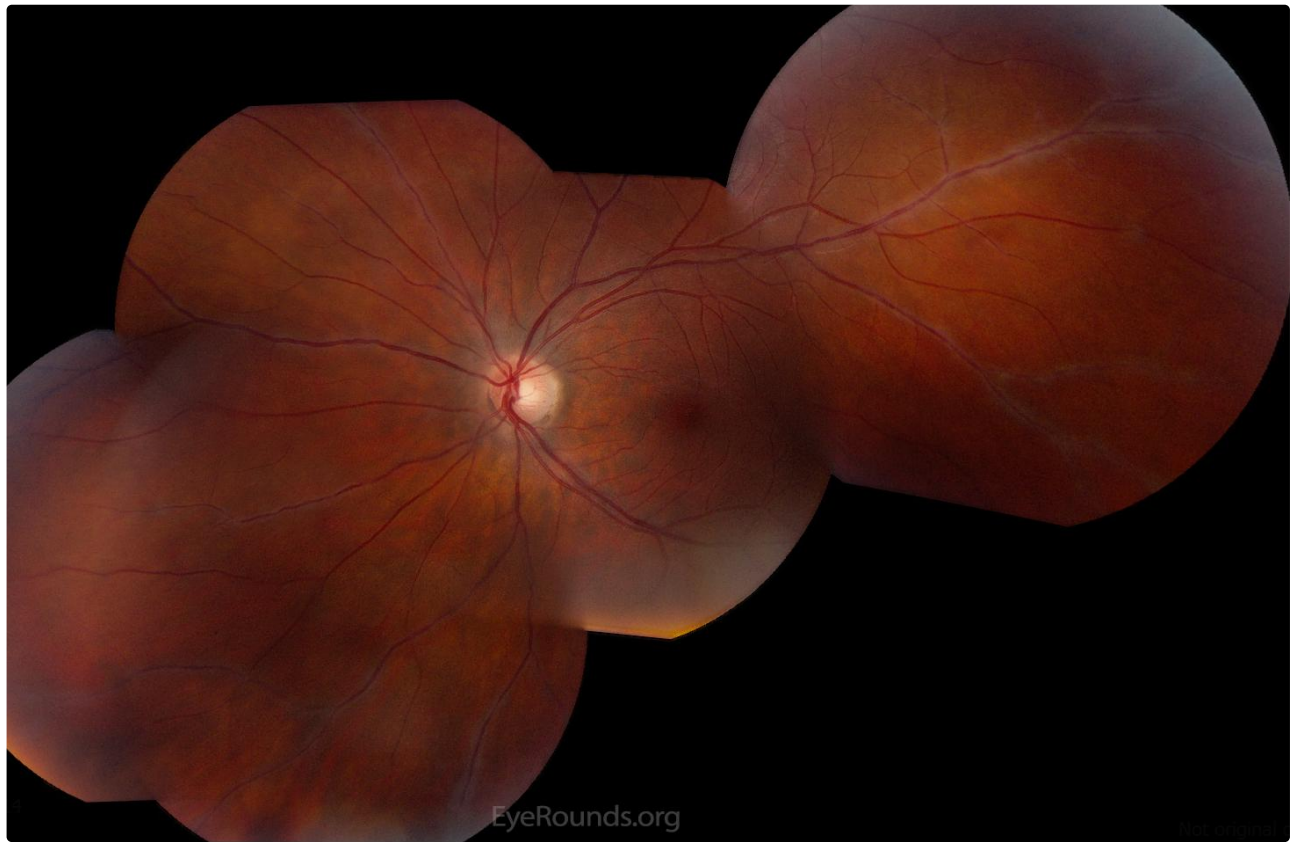
Retinal periphlebitis is a vasculitis of the peripheral retinal vasculature. The faint silvery glow surrounding the peripheral retinal veins in these montage photos depict this.

This case is a young female that presented with non-specific visual complaints and was found to have bilateral retinal periphlebitis. The etiology was undetermined and she was sent on to Neurology to be worked up for multiple sclerosis which can be associated with this condition.



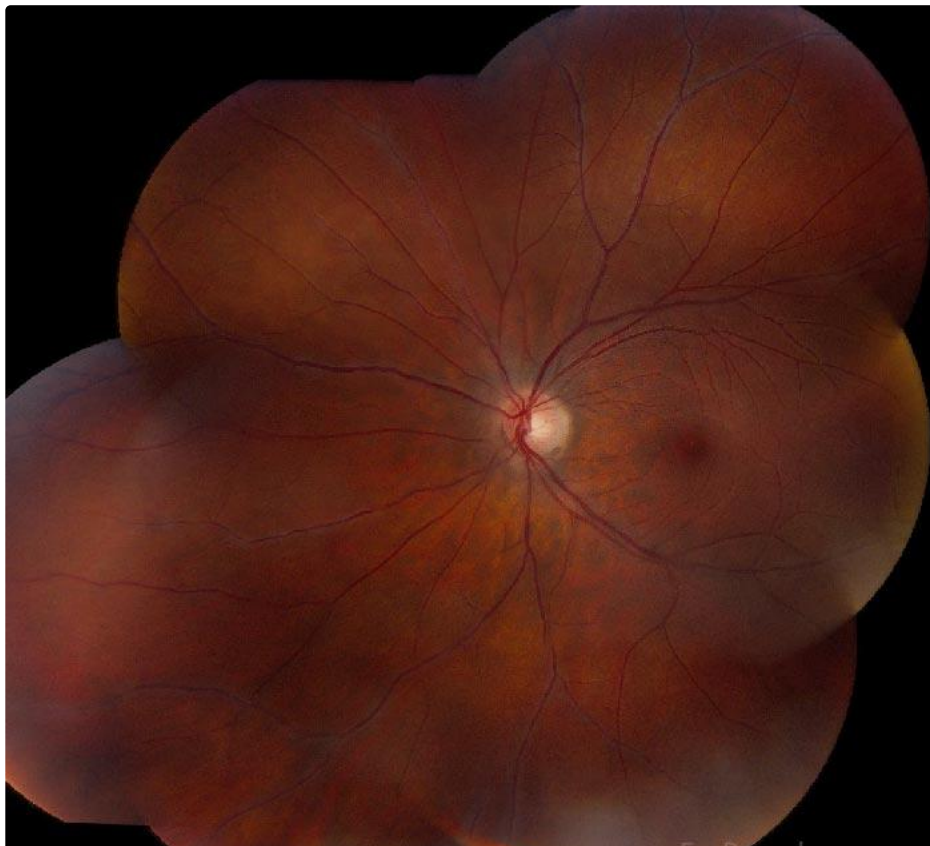[Enlarge](#)

[Download](#)



[Enlarge](#)

[Download](#)



Enlarge

Download

Image Permissions:



Ophthalmic Atlas Images by EyeRounds.org, The University of Iowa are licensed under a Creative Commons Attribution-NonCommercial-NoDerivs 3.0 Unported License.

Address

University of Iowa
Roy J. and Lucille A. Carver College
of Medicine
Department of Ophthalmology and
Visual Sciences
200 Hawkins Drive
Iowa City, IA 52242

[Support Us](#)

Legal

Copyright © 2019 The University of
Iowa. All Rights Reserved
[Report an issue with this page](#)
[Web Privacy Policy](#) |
[Nondiscrimination Statement](#)

Related Links

[Cataract Surgery for Greenhorns](#)
[EyeTransillumination](#)
[Gonioscopy.org](#)
[Iowa Glaucoma Curriculum](#)
[Iowa Wet Lab](#)
[Patient Information](#)
[Stone Rounds](#)
[The Best Hits Bookshelf](#)

EyeRounds Social Media

Follow



Receive notification of new cases,
[sign up here](#)
[Contact Us](#)
[Submit a Suggestion](#)